BJR
© 2021 The Authors. Published by the British Institute of Radiology

https://doi.org/10.1259/bjr.20201013

Received: 19 August 2020 | Revised: 06 January 2021 | Accepted: 12 January 2021

Cite this article as:
Samreen N, Madsen LB, Chacko C, Heller SL. Magnetic resonance imaging in the evaluation of pathologic nipple discharge: indications and imaging findings. *Br J Radiol* 2021; **94**: 20201013.

REVIEW ARTICLE

Magnetic resonance imaging in the evaluation of pathologic nipple discharge: indications and imaging findings

[1]NAZIYA SAMREEN, MD, [2]LAURA B MADSEN, MD, MSc, [1]CELIN CHACKO, MD and [3]SAMANTHA L HELLER, PhD, MD

[1]New York University Long Island Division, Long Island, NY, USA
[2]NYU Winthrop Hospital, Mineola, NY, USA
[3]New York University, Grossman School of Medicine, New York, NY, USA

Address correspondence to: Dr Naziya Samreen
E-mail: *samreen.naziya@gmail.com*

ABSTRACT

Pathologic nipple discharge (PND) is typically unilateral, spontaneous, involves a single duct, and is serous or bloody in appearance. In patients with PND, breast MRI can be helpful as an additional diagnostic tool when conventional imaging with mammogram and ultrasound are negative. MRI is able to detect the etiology of nipple discharge in 56–61% of cases when initial imaging with mammogram and ultrasound are negative. Advantages to using MRI in evaluation of PND include good visualization of the retroareolar breast and better evaluation of posterior lesions which may not be well evaluated on mammograms and galactograms. It is also less invasive compared to central duct excision. Papillomas and nipple adenomas are benign breast masses that can cause PND and are well visualized on MRI. Ductal ectasia, and infectious etiologies such as mastitis, abscess, and fistulas are additional benign causes of PND that are well evaluated with MRI. MRI is also excellent for evaluation of malignant causes of PND including Paget's disease, ductal carcinoma *in-situ* and invasive carcinoma. MRI's high negative predictive value of 87–98.2% is helpful in excluding malignant etiologies of PND.

INTRODUCTION

Dynamic contrast-enhanced MRI (DCE-MRI) of the breast is the most sensitive imaging modality for the detection of breast cancer.[1–4] Indications for performing a breast MRI are variable, and include breast cancer screening in high risk patients, extent of disease evaluation, assessing response to neoadjuvant chemotherapy (NAC), problem-solving inconclusive mammographic/sonographic findings, and guidance for biopsy/localization.[5] In patients with pathologic nipple discharge (PND), breast MRI can be helpful as an additional diagnostic tool when conventional imaging with mammogram and ultrasound are negative. The American College of Radiology (ACR) and the European Society of Breast Imaging (EUSOBI) both support evaluation of PND with MRI when initial diagnostic evaluation with mammogram and ultrasound are negative.[6,7]

According to a recent survey, approximately 58% of academic and private practice radiologists recommended a breast MRI following negative diagnostic work-up in the setting of nipple discharge.[8] Meta-analysis data show MRI has a higher diagnostic performance compared to ductography in the evaluation of PND.[9] The purpose of this review is to discuss the role of MRI in the evaluation of nipple discharge and illustrate MRI appearance of various lesions that can lead to PND.

Evaluation of pathologic nipple discharge

Clinical evaluation

PND is typically unilateral, spontaneous, involves a single duct, and is serous or bloody in appearance.[10] PND can be due to benign or malignant etiologies but requires a complete work-up as underlying malignancy can be present in up to 21% of patients who undergo biopsy.[6] This is in contrast to physiologic nipple discharge which is white, green, or yellow in color, involves multiple ducts, and is often bilateral. Physiologic discharge is benign and additional imaging work-up for breast cancer is not necessary.[5] The likelihood of malignancy in patients with PND increases with age. In patients with PND and no palpable mass, malignancy was seen in 3% of patients <40 years, 10% in patients 40–60 years, and >32% in patients >60 years.[11] An associated palpable finding on physical exam is important to note, as this increases the likelihood of malignancy. A

study of 448 females with nipple discharge showed that the incidence of carcinoma was 61.5% in patients with nipple discharge and associated palpable finding on physical exam, while it was only 6.1% in those without associated palpable abnormality.[12]

Mammogram and ultrasound

Initial imaging evaluation of PND typically begins with a mammogram or ultrasound, depending on patient age and gender. For example, in the United States, mammography is recommended for females aged 40 and older and ultrasound for females less than 30 in this setting. Either mammography or ultrasound may be the initial imaging exam for females between ages 30 and 39.[6] In the United Kingdom, the Royal College of Radiology guidance recommends mammography in patients aged 40 and over, with targeted ultrasound if there is a palpable abnormality and for investigation of a single duct clear or blood-stained discharge. In patients ≥40 years of age with PND, the sensitivity, specificity, positive predictive value and negative predictive value (NPV) of mammogram is 15–68%, 38–98%, 42%, and 90% respectively while that of ultrasound is 56–80, 61–75, 29–39, and 90–91% respectively.[6] When initial diagnostic work-up with mammogram and ultrasound are negative, additional imaging options include galactogram, or MRI. Underlying malignancy in the setting of PND is reported in approximately 2–10% in whom initial diagnostic work-up is negative.[13–15]

Magnetic resonance imaging

MRI is able to detect the etiology of nipple discharge in 56–61% of cases when initial imaging with mammogram and ultrasound are negative (Table 1). In the setting of PND, MRI has a sensitivity of 86–100% for invasive cancer and 40–100% for non-invasive disease.[15,18,20–22] According to a meta-analysis, MRI has a higher sensitivity (92% *vs* 69%) and specificity (76% *vs* 39%) compared to galactogram to identify an etiology of PND.[9] The NPV of MRI is high, ranging between 87% and 98.2% which is helpful in excluding malignant pathology in these patients (Table 1).

MRI's superior ability to aid in the evaluation of nipple discharge is multifactorial. First, it can evaluate the entire breast tissue, rather than galactogram which involves cannulation of a single duct. In addition, MRI can evaluate posterior lesions which may not be evaluated through procedures such as galactogram and central duct excision. MRI also allows good visualization of the retroareolar breast and can identify lesions in this region that were initially not seen on mammogram and ultrasound.[23] MRI is also more tolerable than galactograms, leading to better patient compliance and comfort, and is less dependent on the individual performing the exam.[24]

DCE-MRI performed in the setting of PND should include standard sequences such as a non-contrast fat-saturated T_2 weighted sequence, a non-contrast non-fat-saturated T_1 weighted sequence, a non-contrast fat-saturated T_1 weighted sequence, and three or four fat-saturated dynamic post-contrast T_1 weighted images after intravenous administration of a gadolinium-based agent using a weight-based dosing protocol. In cases where ultrafast imaging is performed, these typically include multiple contrast-enhanced images performed at a high temporal resolution of 4–8 s.[25]

As with performing MRI for any indication, using a high-field-strength magnet (1.5 or 3 T), use of a dedicated breast coil, high-spatial-resolution imaging, and appropriate timing of the dynamic sequences is important to obtain optimal MRI images.[26] Images should be evaluated for any artifacts that may obscure small lesions. Appropriate positioning of the nipples during MRI is especially important for evaluation of PND as inappropriately positioned nipples can mimic a mass. Additionally, nipple compression against the breast coil can decrease blood flow to surrounding tissue and decrease visibility of underlying pathology.[26]

Normal nipple and duct anatomy on MRI

Normal nipple enhancement is important to discern as nipple pathology can lead to nipple discharge. Normal nipple enhancement is typically bilateral and symmetric while suspicious nipple enhancement is typically asymmetric, nodular, discoid, or irregular in appearance.[27,28] The internal enhancement of the nipple is typically of equal or lower intensity compared to the ipsilateral background parenchymal enhancement.[29] Gao et al have recently described the nipple areola complex as consisting of three layers (Figure 1).[29] The first is the superficial layer, a highly vascular epidermis that consists of blood vessels and typically enhances greater than adjacent skin. On MRI, it appears as a thin rim of linear enhancement known as superficial linear enhancement (SLE) and is typically less than 2 mm in thickness. Underneath that is the non-enhancing zone (NEZ), which is comprised predominantly of connective tissue and appears as a zone of non-enhancement immediately underneath the SLE. Deep to that is the papilla, which is made up of lactiferous duct bundles and

Table 1. MRI in patients with pathologic nipple discharge and negative initial mammogram and ultrasound

	# of patients	# of malignancies	# of high risk lesions	Sensitivity (%)	Specificity (%)	PPV (%)	NPV (%)
Morrogh et al[15]	306	30 (10%)	16 (5%)	77	62	56	87
Lorenzon et al[16]	38	5 (13%)	14 (37%)	94.7	78.9	NR	96.2
Lubina et al[17]	33	8 (24%)	13 (39%)	95.7	69.7	60.7	82.1
Bahl et al[18]	83	7 (8%)	12 (14%)	100	68	37	100
Zacharioudakis et al[19]	82	14 (17%)	43 (52%)	85.7	98.5	92.3	97.1

NR, not reported.

Figure 1. Normal nipple enhancement: The most superficial layer, known as SLE, consists of blood vessels and typically enhances greater than adjacent skin. The next layer is the NEZ, which is comprised predominantly of connective tissue. Deep to that is the INE which consists of lactiferous duct bundles and smooth muscles, and represents the majority of nipple enhancement on MRI. INE, internal nipple enhancement; NEZ, non-enhancing zone; SLE, superficial linear enhancement.

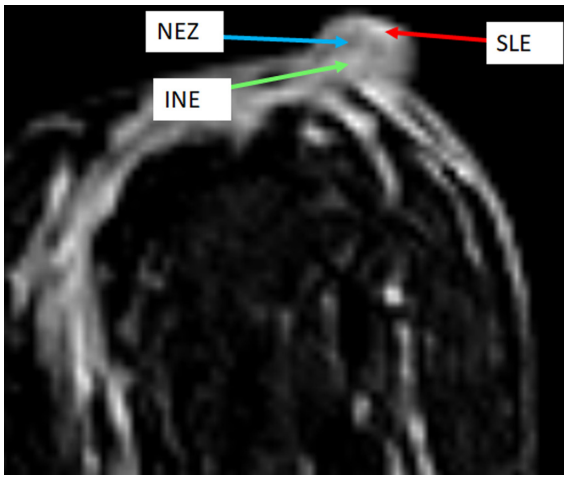

smooth muscles, and constitutes the majority of nipple enhancement noted on MRI. This deep layer of nipple enhancement, known as internal nipple enhancement (INE), can be patchy or linear in appearance depending on the density and distribution of ductal structures.

Normal duct anatomy involves lobules, which secrete products into the lactiferous ducts which then converge as they approach the nipple and subsequently drain into the openings at the nipple. Each nipple is thought to contain between 5 and 9 duct orifices.[30] Normal ducts typically are not visible on MRI unless they are dilated.[30] Inspissated secretions can sometimes cause chronic obstruction and result in duct dilation but this is not considered to be a pathologic process. These inspissation-containing ducts usually appear hyperintense on unenhanced T_1 weighted images secondary to the hemorrhagic/proteinaceous material they contain. They can appear as branching tubular structures usually without associated enhancement.[30] Subtraction sequences on MRI can be helpful in evaluation of ductal enhancement as they suppress the non-enhancing intrinsic T1-hyperintensity within the ducts (Figure 2).

MR imaging appearance of lesions causing pathologic nipple discharge

Lesions which can be seen in cases of PND include papillary lesions, spectrum of ductal ectasia and periductal mastitis including abscess and fistula formation, nipple adenoma, Paget's disease, ductal carcinoma *in-situ* and invasive ductal or lobular carcinoma.

Papillary lesions

Papilloma or papillomatosis is seen in approximately 35–48% of cases of PND.[31] Papillomas can be central or peripheral, and can occur as solitary or multiple lesions. Central papillomas are typically larger and solitary, and are associated with a 1.5- to 2-fold increased risk of breast cancer.[32,33] Central papillomas are more likely to cause nipple discharge compared to peripheral papillomas.[34] Peripheral papillomas are typically multiple, bilateral, and are associated with a higher risk for malignancy.[32,33] The upgrade rate to malignancy ranges widely between 2.3 and 39%, with higher upgrade rates noted in cases of atypia on pathology.[35] Juvenile papillomatosis, a combination of papillomatosis and cyst formation, typically seen in young females with a family history of breast cancer, can also rarely cause pathologic nipple discharge.[36–38]

In patients with nipple discharge, MRI has a sensitivity of up to 90% in detection of papillary lesions.[39] On MRI, papillomas more commonly present as a well-circumscribed round or oval mass (61.4%), but can also present as an irregular mass (38.6%). Enhancement kinetics typically demonstrate a Type 3 washout type curve in most cases (72%) with rapid uptake and washout, but a minority of papillomas demonstrate a Type 2 plateau type enhancement curve (Figure 3).[40] Slice thickness and spatial resolution are important factors to consider in the diagnosis of papillomas on MRI as papillomas that are typically small in size, measuring 1–2 mm, can be MRI occult.[39,40] Studies using a high in-plane spatial resolution of 0.137 mm and a low slice thickness of 1.6 mm have reported a much higher detection of papillomas compared to those with a higher slice thickness of 2–3 mm and a lower in-plane resolution of 0.3–0.7 mm.[40] Papillomatosis and malignant papillary lesions are more likely to present as segmental non-mass enhancement (NME) compared to solitary benign papillomas.[39] Ductal dilation is a common finding in cases of papilloma, with most cases showing distal ductal dilation.[40] Signal within the duct may be hyperintense or hypointense on both T_1 and T_2 weighted imaging depending on presence or absence of blood products, and the age of blood products.[39]

Duct ectasia/periductal mastitis

Ductal ectasia, a benign cause of nipple discharge, has been reported in 6–59% of discharge cases and can be infectious or inflammatory in etiology.[23] The degree of ductal dilation can be variable, ranging from just above the normal diameter of 0.5–1 mm to ≥5 mm.[41] Ductal ectasia typically occurs within 2–3 cm of the nipple but can occasionally extend further peripherally. Intraductal contents are variable, and can include cellular debris, fatty acid crystals, or inflammatory cells (Figure 2).[41] MRI is helpful to rule out enhancing lesions within the ductal lumen or duct wall that may be confused with benign ductal ectasia.[30]

Periductal mastitis is an inflammatory process involving the ducts that can lead to pathologic nipple discharge.[42] The inflammatory process can extend into surrounding breast tissue and occasionally form an inflammatory mass.[41] Mastitis on MRI can present as an enhancing mass or NME, with associated findings such as with skin thickening, increase in breast size, abnormal nipple configuration, and prominent blood vessels (Figure 4).[43] Increased edema within the skin and breast tissue can appear as hyperintense signal on T_2 weighted sequences.[44]

Figure 2. Ductal ectasia: 47-year-old female with left bloody nipple discharge. No abnormality was noted on mammogram, and ultrasound demonstrated dilated ducts with fluid. T_1 weighted fat suppressed (a), T_1 weighted non-fat suppressed (b) and T_2 weighted (c) sequences demonstrate proteinaceous debris/blood (arrow) in the branching, mildly dilated ductal system upper inner periareolar region. No abnormal enhancement in the ducts or periductal region (circle) is noted on the ultrafast fat suppressed contrast-enhanced sequence (d) or the axial T_1 weighted fat suppressed contrast-enhanced fat suppressed sequence (e). Surgical consultation was recommended due to atypia noted on cytology from expressed fluid. Ductal excision was performed which demonstrated benign findings including mammary duct ectasia, cystic apocrine hyperplasia, and a 1mm small intraductal papilloma.

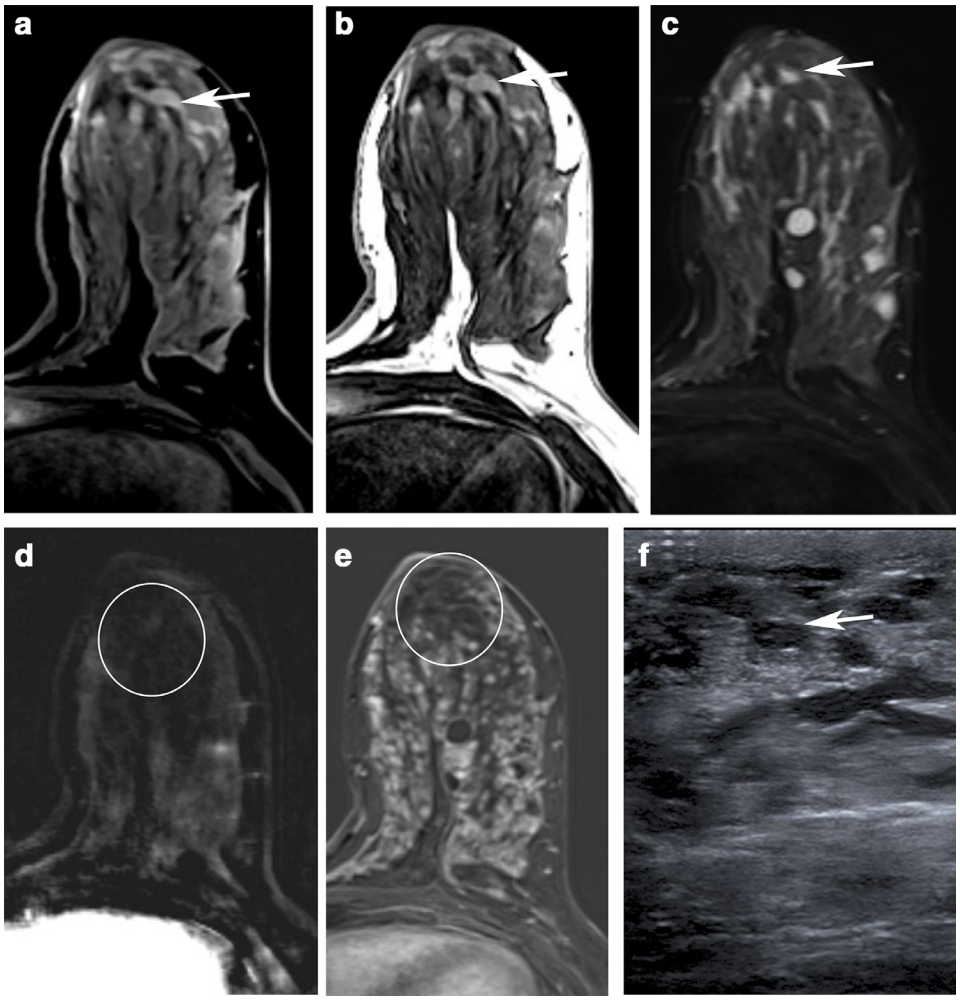

Abscess formation can result as a complication from inflammatory processes such as granulomatous mastitis or mastitis due to bacterial pathogens.[41] MRI can detect microabscesses of only a few millimeters in size.[45] Breast abscess on MRI most often presents as peripheral rim enhancement on contrast-enhanced sequences and is hyperintense on T_2 weighted imaging (Figure 5).[46] Abscesses may be accompanied by surrounding edema which is also hyperintense on T_2 weighted images.[45]

Recurrent abscess formation can lead to development of mammary duct fistulas, some of which can spontaneously drain to the skin.[41] On MRI, fistulas typically demonstrate wall enhancement and a track leading to the skin may be present (Figure 5).[47] There can be enhancement in the surrounding breast tissue due to the inflammatory changes. Post-contrast MRI imaging with a small surface microscopy coil can help with improved visualization of fistulas that are as small as 1 mm.[48] This is especially helpful if the fistula is located within the nipple, as some of these may not be visualized on ultrasound.[48]

Nipple adenoma

Nipple adenoma is an uncommon benign breast tumor involving the nipple–areola complex that results from proliferation of small tubules surrounding the collecting ducts of the nipple.[49,50] Imaging features can be variable as there are four different histologic patterns of nipple adenoma: adenosis, epithelial hyperplasia or papillomatosis, sclerosing papillomatosis or pseudoinfiltrating, or mixed.[51] Adenomas can demonstrate homogenous enhancement or a peripheral rim enhancement pattern secondary to abundant vessels in the periphery.[52,53] On T_2 weighted sequences, they are typically hyperintense, although T2-hypointense lesions have been described (Figure 6).[53,54] A rapid uptake and washout

Figure 3. Papilloma: 39-year-old female with clear left nipple discharge and outside ultrasound demonstrating no sonographic abnormality in the left retroareolar region. MRI was performed for further evaluation. In the left breast at 8:00, 4 cm posterior to the nipple, a 0.8 cm oval mass enhancing mass (circle) seen on the axial fat suppressed subtraction contrast-enhanced sequence (a). On ultrafast imaging axial post-contrast subtraction sequence (b), the mass (circle) demonstrated rapid wash-in. The mass (circle) was seen on the maximum intensity projection of the ultrafast sequences (c). The mass (circle) is hyperintense on the T_2 weighted sequence (d). (e) An MRI directed ultrasound was performed which demonstrated a 0.8 × 0.7 x 0.6 cm oval, hypoechoic mass (circle) with indistinct margins, correlating to the finding on recent breast MRI. Ultrasound guided biopsy was performed which demonstrated a papilloma. Patient was referred for surgical excision.

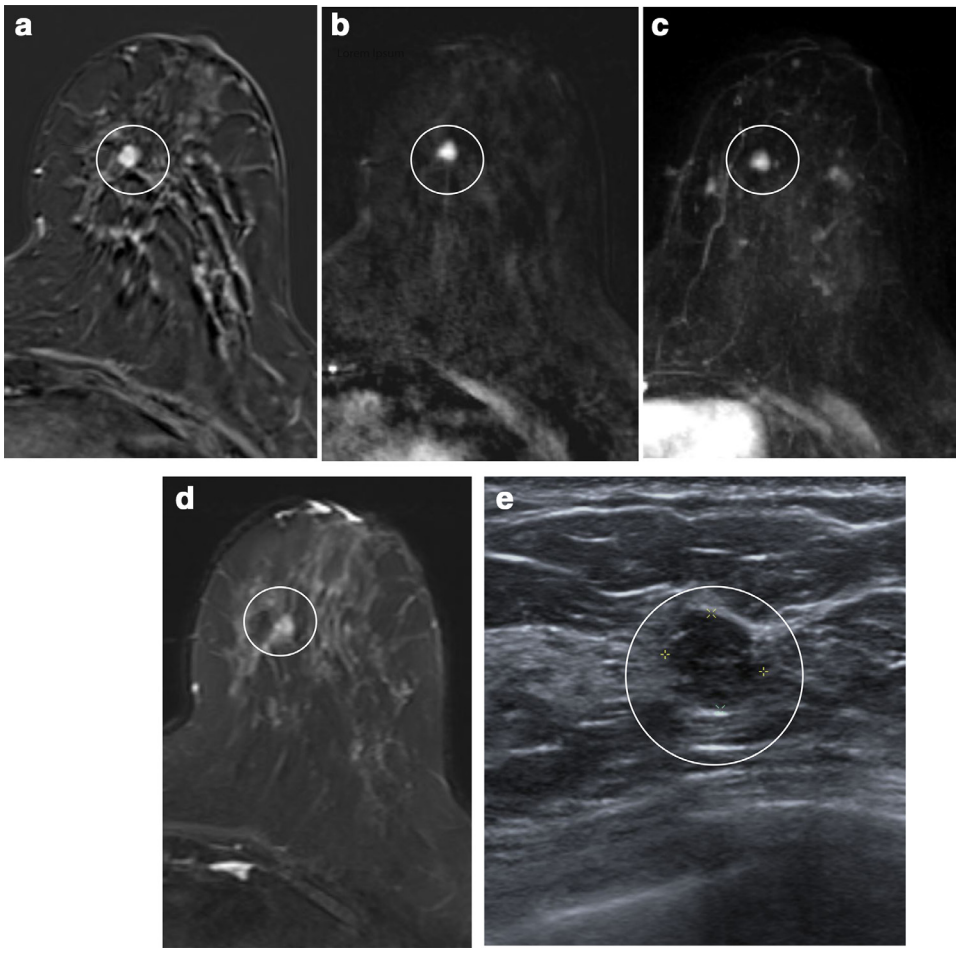

type kinetic pattern is more common, although a plateau type enhancement curve has also been described.[52,53,55]

Paget's disease

Paget's disease, a cause of bloody nipple discharge, is a malignant condition in which the nipple epidermis is infiltrated by adenocarcinoma.[56–58] In patients with Paget's disease, underlying malignancy is noted in over 90% of cases, typically presenting as ductal carcinoma in situ (DCIS) or invasive breast cancer.[57,59] Paget's disease is multifocal in 41% of cases and multicentric in 34% of cases.[60] MRI can play an important role in evaluation of patients with suspected Paget's disease as mammograms can be negative in up to 50% of patients.[61] On MRI, Paget's disease may present as thickening and enhancement of the nipple–areolar complex which is asymmetric to the other side (Figure 7).[62] Associated findings suggestive of underlying DCIS or malignancy may also be present, including mass or non-mass enhancement.

DCIS

DCIS is characterized by proliferation of malignant cells that line a terminal ductal-lobular unit without invasion through the basement membrane.[63] Of patients with PND who are diagnosed with malignancy, the majority are DCIS (60–86%) with invasive cancer being less common (14–40%).[64,65] Up to 10.6% of patients with DCIS present with bloody or serous nipple discharge.[66] In patients with PND, MRI can identify a subset of DCIS that does not present with calcifications on mammogram, and therefore may be mammographically occult.[19] MRI has a higher sensitivity compared to mammogram for detection of DCIS, and the sensitivity varies according to the grade of DCIS. Sensitivity is lowest for low-grade DCIS (80%), and higher for intermediate-grade (91%) and high-grade (98%) DCIS.[67]

DCIS most commonly presents as non-mass enhancement on MRI (60–81%), and less commonly as a mass (14–41%) or focus

Figure 4. Mastitis/Chronic inflammation: 47-year-old female with history of right nipple discharge. (A) Axial T_2 weighted sequence demonstrates dilated retroareolar ducts (arrow) containing hyperintense material. The proteinaceous material within the ducts (arrow) is also hyperintense on the noncontrast fat suppressed T_1 weighted sequence (B). There is segmental clumped non-mass enhancement (arrow) surrounding the ducts on the contrast-enhanced T_1 weighted sequence (C). Patient underwent MRI-guided biopsy which demonstrated ductal ectasia and periductal chronic inflammation. Follow-up MRI demonstrated decreased enhancement also supporting benign etiology.

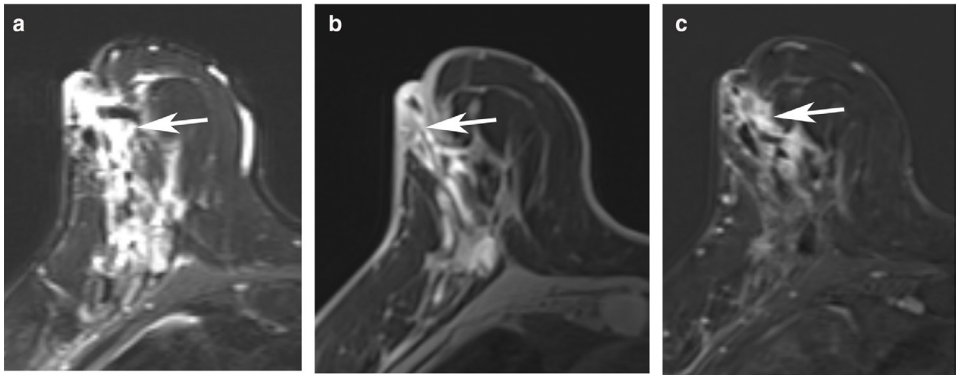

(1–12%) (Figure 8).[68] When presenting as NME, DCIS is most commonly segmental with a clumped or heterogeneous pattern. Clustered ring enhancement, a subtype of NME added to the fifth edition of the Breast Imaging Reporting and Data System (BI-RADS) manual, has a specificity of up to 63% for DCIS.[69] When presenting as a mass, DCIS is most commonly irregular in morphology.[68] The kinetic enhancement pattern is variable, with frequency of a persistent, plateau, and washout types curves being 20–30, 20–52, and 28–44% respectively.[70–72] A rapid washout pattern is more commonly seen with high-grade DCIS, which may be due to its increased vascularity.[67,68] False-negative cases of DCIS on MRI may occur due to the lower amount of angiogenesis within the DCIS or low spatial resolution of the MRI image.[73]

Figure 5. Granulomatous inflammation/abscess: 58-year-old female with history of right breast palpable lump and nipple discharge, status post-ultrasound-guided core biopsy yielding acute and chronic non-necrotizing granulomatous inflammation. MRI was performed for worsening symptoms. (A) MRI demonstrates a T2-hyperintense fluid collection with septations (circle). (B) The fluid collection is hypointense on the fat suppressed T_1 weighted sequence (circle). (C) Axial fat suppressed contrast-enhanced sequence demonstrates enhancement within the rim of the fluid collection as well as within the septations (circle). (D) On the sagittal contrast-enhanced sequence, the abscess is again seen (circle), and multiple fistulas are noted extending to the skin (arrow). Findings are compatible with granulomatous abscess and fistula formation.

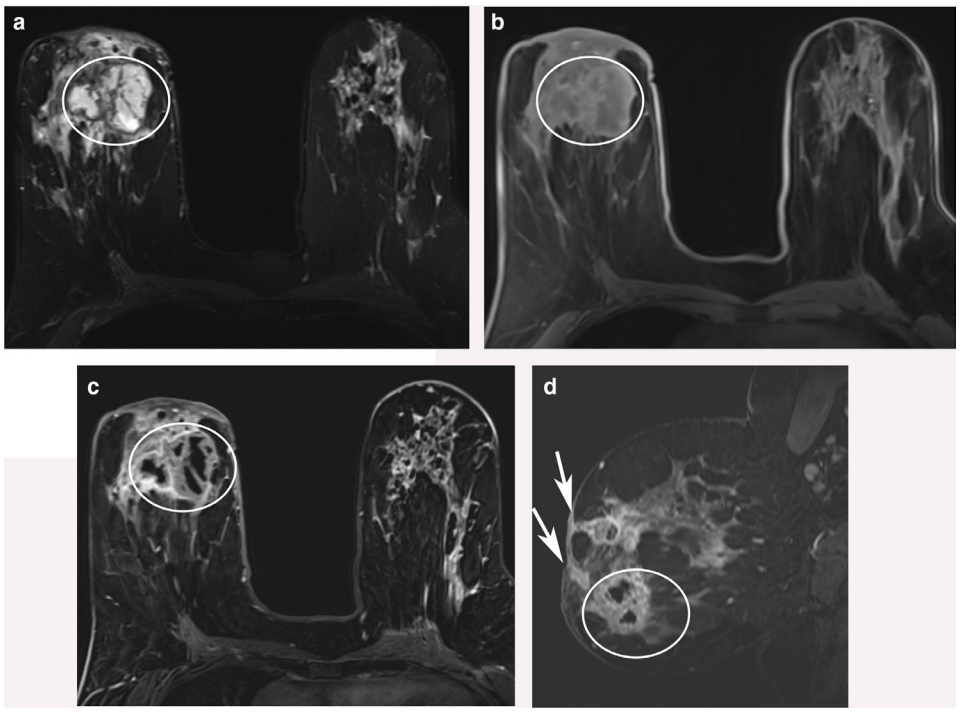

Figure 6. Nipple adenoma: 23-year-old female with family history of breast cancer. MRI was obtained due to right nipple pain, discharge and swelling. (A) MRI demonstrated an enlarged nipple on the right that was hyperintense on the T_2 weighted sequence (circle). (B) On the fat suppressed contrast-enhanced sequence, there is asymmetric enhancement and enlargement of the right nipple (circle) with no additional abnormal enhancement within the right breast. (C) The asymmetric nipple enhancement and enlargement is well seen on the maximum intensity projection (circle). A right nipple incisional biopsy was performed which demonstrated nipple adenoma.

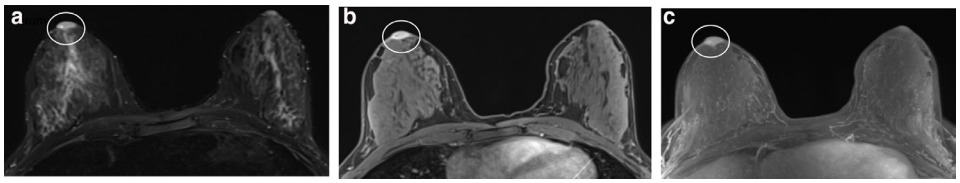

Invasive carcinoma

Invasive carcinomas, including those with ductal, lobular, or papillary histology, can also present with pathologic nipple discharge. MRI has a high sensitivity of 93–100% for the detection of invasive breast carcinoma.[5] Invasive ductal carcinoma (IDC) can have variable presentations on MRI. It most commonly is seen as an enhancing mass with plateau or washout type kinetics, but can also appear as non-mass enhancement or a focus.[74] When it presents as non-mass enhancement, the distribution and internal enhancement characteristics are variable, but one study suggests that clumped NME may have worse prognosis in patients with IDC compared to other enhancement patterns.[75]

MRI has a sensitivity of approximately 93.3% for invasive lobular carcinoma (ILC).[76] On MRI, ILC most commonly presents as a solitary mass with irregular or angular shape and spiculated or ill-defined margins.[77] Other manifestations include multiple small enhancing foci surrounding a dominant lesion, distortion, enhancing septations, or non-mass enhancement (typically in a regional or focal distribution).[77] In patients with ILC, MRI can alter clinical management in up to 50% of patients and surgical management in 28% of cases.[76] A meta-analysis demonstrated that MRI can detect additional ipsilateral findings in 32% of patients with ILC and contralateral malignancy in 7% of cases.[76]

Figure 7. Paget's disease: 83-year-old female presenting with right nipple erythema, discharge, and skin changes. (A) Axial fat suppressed contrast-enhanced MRI sequence demonstrates marked enhancement of the right nipple (circle) suspicious for Paget's disease. There is linear non-mass enhancement extending posteriorly, well seen on the maximum intensity projection image (B) and the sagittal sequence (D), highly concerning for additional disease. (C) The enlarged right nipple with Paget's disease is hypointense on the T_2 weighted sequence. Right nipple punch biopsy demonstrated Paget's disease. Lumpectomy demonstrated DCIS with involvement of the nipple epidermis, consistent with Paget's disease. DCIS, ductal carcinoma *in situ*.

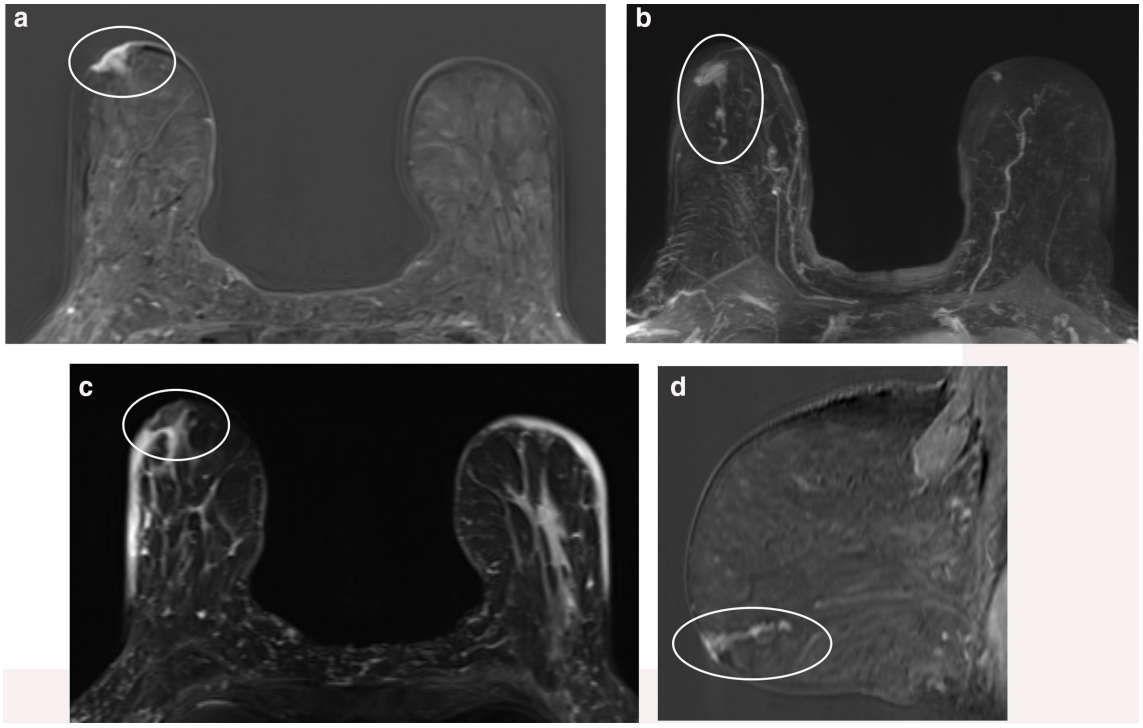

Figure 8. DCIS: 64-year-old postmenopausal female with right breast clear nipple discharge. (a) Mammogram demonstrated loosely grouped coarse heterogenous calcifications in the lower central right breast with associated focal asymmetry (circle). (b) Ultrasound demonstrated a 1.8 × 0.7 x 0.9 cm hypoechoic mass with occasional angular margins (square), corresponding to the focal asymmetry and calcifications on mammography. Ultrasound-guided biopsy was performed which demonstrated ductal carcinoma *in situ*, papillary and cribriform type, intermediate grade, with central necrosis. MRI performed for surgical planning. (c) The axial contrast-enhanced subtraction VIBE sequence demonstrated right breast extensive segmental non-mass enhancement on (circle) measuring 10.3 cm in the AP dimension, consistent with biopsy-proven DCIS. (d) Similar pattern of contrast enhancement is noted on the ultrafast sequence (circle), which demonstrates a slightly lower resolution. (e) The maximum intensity projection from the ultrafast sequence well demonstrates the non-mass enhancement (circle). (f) The biopsy proven DCIS is hyperintense on the T_2 weighted sequence (circle). (g) The sagittal demonstrates also demonstrates the non-mass enhancement (circle). AP, Anteroposterior; DCIS, Ductal carcinoma *in situ*; VIBE, Volumetric interpolated breath-hold,

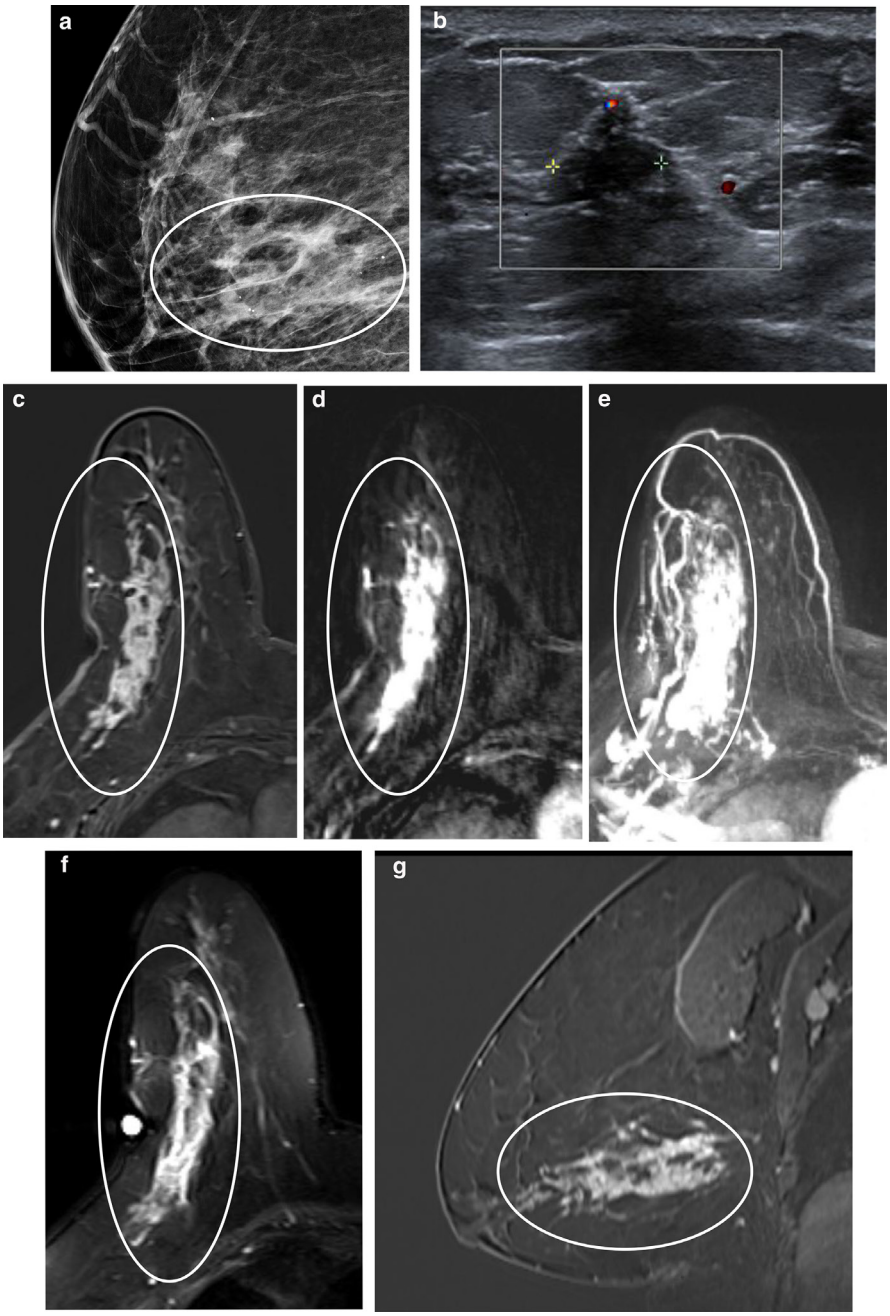

Papillary carcinomas, which account for approximately 0.5% of newly diagnosed breast cancers, can also cause pathologic nipple discharge.[78] These can be intraductal (*i.e.* extending through a ductal system), intracystic, or can rarely extend into adjacent breast tissue.[78] On MRI, they may appear as irregular enhancing masses or complex solid and cystic masses.[79]

Figure 9. Inflammatory breast carcinoma: 30-year-old post-partum female with pain and swelling in the left breast, treated with antibiotics without improvement. Skin thickening was noted on physical exam and punch biopsy demonstrated inflammatory carcinoma. MRI was obtained to evaluate extent of disease. (a) T_2 weighted sequence demonstrates diffuse left breast skin thickening and edema (circle) which appears hyperintense and asymmetric to right. (b) Axial and sagittal (d) fat suppressed contrast-enhanced sequence demonstrates enhancement in the skin as well as extensive non-mass enhancement within the breast which extends to the nipple anteriorly (circle). (c) The skin thickening and non-mass enhancement in the breast is well seen on the maximum intensity projection image. Enlarged left axillary lymph nodes are also noted (arrow).

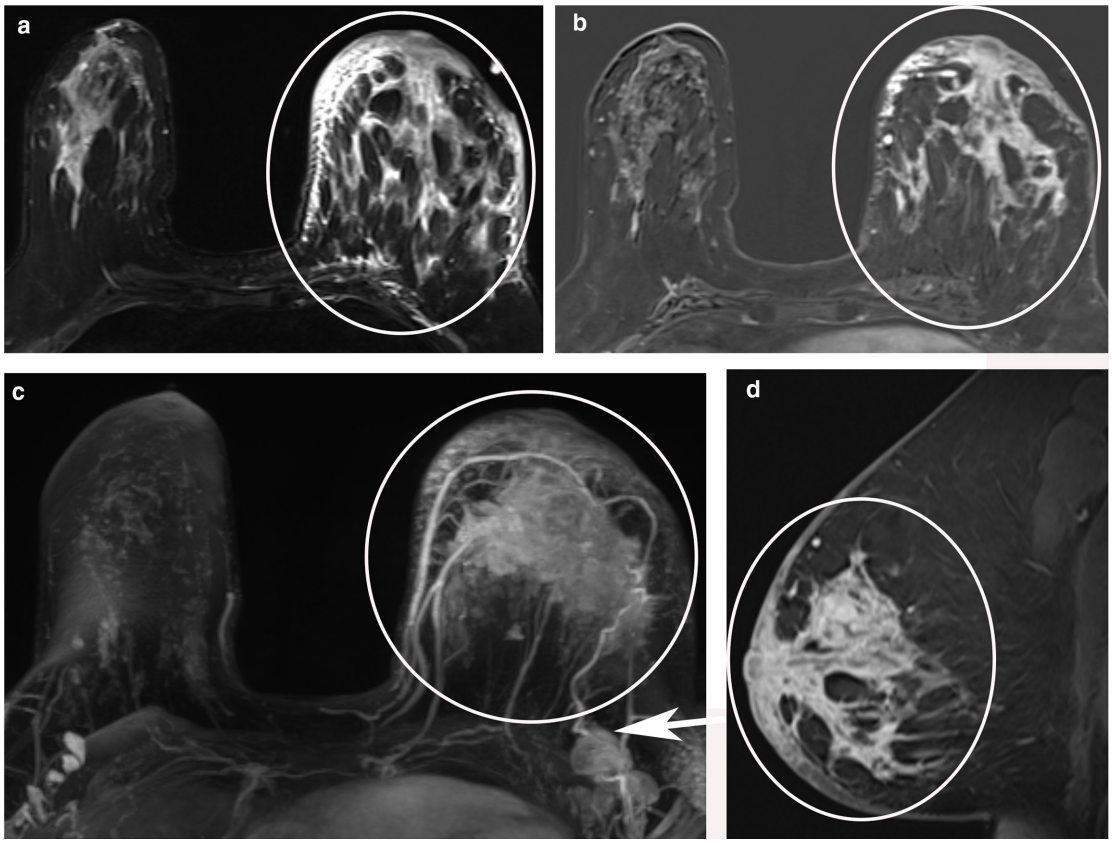

Inflammatory breast cancer is a rare and aggressive form of invasive breast cancer that involves the dermal lymphatics and is characterized by its rapid progression.[80,81] Skin changes are caused by tumor emboli in the dermal lymphatics, leading to considerable edema and inflammation of the skin and there may be associated nipple changes and discharge.[82] Underlying tumor pathology can be IDC, ILC, or mixed.[83] Typical MRI findings include global skin thickening, breast enlargement, breast and chest wall edema, and breast mass (Figure 9).[84] It may be difficult to differentiate inflammatory breast cancer from mastitis with imaging alone.

Management of MRI findings and surgical considerations

In patients with suspicious findings on MRI, further management typically includes MRI-guided biopsy or a MRI directed ultrasound with subsequent ultrasound-guided biopsy. Ultrasound sometimes is able to further characterize MRI findings and a biopsy may be avoided if findings that were suspicious on MRI appear benign on ultrasound. Ultrasound-guided biopsy is preferable to MRI-guided biopsies as it is less expensive, less uncomfortable for the patient, and more convenient.[85] MRI-directed ultrasound is most helpful in findings that present as a mass or focus rather than non-mass enhancement as a study of 202 MRI detected lesions reported sonographic correlates in 67% of masses, 46% of foci, and 12% of non-mass enhancement noted on MRI.[85]

In cases of PND where no abnormality is noted on conventional work-up with mammogram and ultrasound, patients should be referred for surgical consultation. It has been proposed by Panzironi et al[86] that in patients with PND who have negative findings on mammogram, ultrasound, and MRI, follow-up routine screening imaging is appropriate if discharge does not require symptomatic relief and is not persistent.[87] However, patients may require surgical intervention depending on symptoms; *e.g.* if bloody or clear spontaneous unilateral discharge is persistent, or accompanied by suspicious clinical signs such as clinically concerning lump or skin changes. In such cases, a total subareolar duct excision (major duct excision) or a selective duct excision of a single duct may be surgically performed.[86] Performing a central duct excision after negative initial findings on mammogram and ultrasound without subsequent MRI may be suboptimal as this approach may not always identify a cause

of nipple discharge. This is especially true in cases where the abnormality is >3 cm beyond the nipple and may not be excised with a central duct excision.[88]

In patients with PND and biopsy-proven malignancy, MRI may be helpful in establishing whether disease involves the nipple to aid in surgical planning as data from mastectomy specimens show that unexpected nipple involvement is seen in 10–60% of breast malignancies.[89–91] In cases where PND is due to underlying malignancy, MRI has a high sensitivity of up to 90–100% and a moderate specificity of 80–90% in the evaluation of the nipple areola complex for breast cancer invasion.[92,93] MRI is most helpful due to its high NPV of 97–98% in assessment of the nipple–areola complex to exclude involvement by malignancy.[94] Traditionally, a tumor-to-nipple distance of >2 cm has been a criteria for nipple sparing mastectomy. However, recent data show that a tumor-to-nipple distance of ≥1 cm but ≤2 cm as measured by MRI may not be a contraindication for nipple-sparing mastectomy.[95]

CONCLUSION

PND is a relatively common presenting breast complaint and imaging evaluation depends on patient age. MRI should be considered as an additional diagnostic tool when initial imaging work-up with mammogram and ultrasound are negative and there is clinical suspicion for underlying malignancy. MRI has high sensitivity for detection of nipple and ductal pathology, which are common causes of PND.

REFERENCES

1. Milon A, Wahab CA, Kermarrec E, Bekhouche A, Taourel P, Thomassin-Naggara I. Breast MRI: is faster better? *AJR Am J Roentgenol* 2020; **214**: 282–95. doi: https://doi.org/10.2214/AJR.19.21924
2. Peters NHGM, Borel Rinkes IHM, Zuithoff NPA, Mali WPTM, Moons KGM, Peeters PHM. Meta-analysis of Mr imaging in the diagnosis of breast lesions. *Radiology* 2008; **246**: 116–24. doi: https://doi.org/10.1148/radiol.2461061298
3. Medeiros LR, Duarte CS, Rosa DD, Edelweiss MI, Edelweiss M, Silva FR, et al. Accuracy of magnetic resonance in suspicious breast lesions: a systematic quantitative review and meta-analysis. *Breast Cancer Res Treat* 2011; **126**: 273–85. doi: https://doi.org/10.1007/s10549-010-1326-9
4. Bennani-Baiti B, Baltzer PA. Mr imaging for diagnosis of malignancy in mammographic microcalcifications: a systematic review and meta-analysis. *Radiology* 2017; **283**: 692–701. doi: https://doi.org/10.1148/radiol.2016161106
5. ACoR.Acrpractice parameterfor the performance of contrast-enhanced magnetic resonance imaging (MRI) of the breast. 2018. Available from: https://www.acr.org/-/media/ACR/Files/Practice-Parameters/MR-Contrast-Breast.pdf.
6. Lee S-J, Trikha S, Moy L, Baron P, diFlorio RM, Green ED, et al. ACR appropriateness criteria ® evaluation of nipple discharge. *J Am Coll Radiol* 2017; **14**(5s): S138–53. doi: https://doi.org/10.1016/j.jacr.2017.01.030
7. Mann RM, Balleyguier C, Baltzer PA, Bick U, Colin C, Cornford E, et al. Breast MRI: EUSOBI recommendations for women's information. *Eur Radiol* 2015; **25**: 3669–78. doi: https://doi.org/10.1007/s00330-015-3807-z
8. Patel BK, Ferraro C, Kosiorek HE, Loving VA, D'Orsi C, Newell M, et al. Nipple discharge: imaging variability among U.S. radiologists. *AJR Am J Roentgenol* 2018; **211**: 920–5. doi: https://doi.org/10.2214/AJR.18.19622
9. Berger N, Luparia A, Di Leo G, Carbonaro LA, Trimboli RM, Ambrogi F, et al. Diagnostic performance of MRI versus Galactography in women with pathologic nipple discharge: a systematic review and meta-analysis. *AJR Am J Roentgenol* 2017; **209**: 465–71. doi: https://doi.org/10.2214/AJR.16.16682
10. Alcock C, Layer GT. Predicting occult malignancy in nipple discharge. *ANZ J Surg* 2010; **80**: 646–9. doi: https://doi.org/10.1111/j.1445-2197.2010.05270.x
11. Seltzer MH. Breast complaints, biopsies, and cancer correlated with age in 10,000 consecutive new surgical referrals. *Breast J* 2004; **10**: 111–7. doi: https://doi.org/10.1111/j.1075-122X.2004.21284.x
12. Gülay H, Bora S, Kilìçturgay S, Hamaloğlu E, Göksel HA. Management of nipple discharge. *J Am Coll Surg* 1994; **178**: 471–4.
13. Sabel MS, Helvie MA, Breslin T, Curry A, Diehl KM, Cimmino VM, et al. Is duct excision still necessary for all cases of suspicious nipple discharge? *Breast J* 2012; **18**: 157–62. doi: https://doi.org/10.1111/j.1524-4741.2011.01207.x
14. Gray RJ, Pockaj BA, Karstaedt PJ. Navigating murky waters: a modern treatment algorithm for nipple discharge. *Am J Surg* 2007; **194**: 850–5. doi: https://doi.org/10.1016/j.amjsurg.2007.08.027
15. Morrogh M, Morris EA, Liberman L, Borgen PI, King TA. The predictive value of ductography and magnetic resonance imaging in the management of nipple discharge. *Ann Surg Oncol* 2007; **14**): : 3369–77p.. doi: https://doi.org/10.1245/s10434-007-9530-5
16. Lorenzon M, Zuiani C, Linda A, Londero V, Girometti R, Bazzocchi M. Magnetic resonance imaging in patients with nipple discharge: should we recommend it? *Eur Radiol* 2011; **21**: 899–907. doi: https://doi.org/10.1007/s00330-010-2009-y
17. Lubina N, Schedelbeck U, Roth A, Weng AM, Geissinger E, Hönig A, et al. 3.0 Tesla breast magnetic resonance imaging in patients with nipple discharge when mammography and ultrasound fail. *Eur Radiol* 2015; **25**: 1285–93. doi: https://doi.org/10.1007/s00330-014-3521-2
18. Bahl M, Baker JA, Greenup RA, Ghate SV. Evaluation of pathologic nipple discharge: what is the added diagnostic value of MRI? *Ann Surg Oncol* 2015; **22 Suppl 3**(Suppl 3): 435–41. doi: https://doi.org/10.1245/s10434-015-4792-9
19. Zacharioudakis K, Kontoulis T, Vella JX, Zhao J, Ramakrishnan R, Cunningham DA, et al. Can we see what is invisible? the role of MRI in the evaluation and management of patients with pathological nipple discharge. *Breast Cancer Res Treat* 2019; **178**: 115–20. doi: https://doi.org/10.1007/s10549-019-05321-w
20. Nakahara H, Namba K, Watanabe R, Furusawa H, Matsu T, Akiyama F, et al. A comparison of Mr imaging, galactography and ultrasonography in patients with nipple discharge. *Breast Cancer* 2003; **10**: 320–9. doi: https://doi.org/10.1007/BF02967652
21. Manganaro L, D'Ambrosio I, Gigli S, Di Pastena F, Giraldi G, Tardioli S, et al. Breast MRI in patients with unilateral bloody and serous-bloody nipple discharge: a comparison with galactography. *Biomed Res*

Int 2015; **2015**: 1–9. doi: https://doi.org/10.1155/2015/806368
22. van Gelder L, Bisschops RHC, Menke-Pluymers MBE, Westenend PJ, Plaisier PW. Magnetic resonance imaging in patients with unilateral bloody nipple discharge; useful when conventional diagnostics are negative? *World J Surg* 2015; **39**: 184–6. doi: https://doi.org/10.1007/s00268-014-2701-1
23. de Paula IB, Campos AM. Breast imaging in patients with nipple discharge. *Radiol Bras* 2017; **50**: 383–8. doi: https://doi.org/10.1590/0100-3984.2016.0103
24. Berger N, Luparia A, Di Leo G, Carbonaro LA, Trimboli RM, Ambrogi F, et al. Diagnostic performance of MRI versus Galactography in women with pathologic nipple discharge: a systematic review and meta-analysis. *AJR Am J Roentgenol* 2017; **209**: 465–71. doi: https://doi.org/10.2214/AJR.16.16682
25. Onishi N, Sadinski M, Hughes MC, Ko ES, Gibbs P, Gallagher KM, et al. Ultrafast dynamic contrast-enhanced breast MRI may generate prognostic imaging markers of breast cancer. *Breast Cancer Res* 2020; **22**: 58. doi: https://doi.org/10.1186/s13058-020-01292-9
26. Yeh ED, Georgian-Smith D, Raza S, Bussolari L, Pawlisz-Hoff J, Birdwell RL. Positioning in breast MR imaging to optimize image quality. *Radiographics* 2014; **34**: E1–17. doi: https://doi.org/10.1148/rg.341125193
27. Friedman EP, Hall-Craggs MA, Mumtaz H, Schneidau A. Breast MR and the appearance of the normal and abnormal nipple. *Clin Radiol* 1997; **52**: 854–61. doi: https://doi.org/10.1016/S0009-9260(97)80081-5
28. Da Costa D, Taddese A, Cure ML, Gerson D, Poppiti R, Esserman LE. Common and unusual diseases of the Nipple-Areolar complex. *Radiographics* 2007; **27**(suppl_1): S65–77. doi: https://doi.org/10.1148/rg.27si075512
29. Gao Y, Brachtel EF, Hernandez O, Heller SL, et al. An analysis of nipple enhancement at breast MRI with Radiologic-Pathologic correlation. *Radiographics* 2019; **39**: 10–27. doi: https://doi.org/10.1148/rg.2019180039
30. Ferris-James DM, Iuanow E, Mehta TS, Shaheen RM, Slanetz PJ, et al. Imaging approaches to diagnosis and management of common ductal abnormalities. *Radiographics* 2012; **32**: 1009–30. doi: https://doi.org/10.1148/rg.324115150
31. Cohen E, Leung JWT. Problem-solving MR imaging for equivocal imaging findings and indeterminate clinical symptoms of the breast. *Magn Reson Imaging Clin N Am* 2018; **26**: 221–33. doi: https://doi.org/10.1016/j.mric.2017.12.012
32. Yang WT, Suen M, Metreweli C. Sonographic features of benign papillary neoplasms of the breast: review of 22 patients. *J Ultrasound Med* 1997; **16**: 161–8. doi: https://doi.org/10.7863/jum.1997.16.3.161
33. Cardenosa G, Eklund GW. Benign papillary neoplasms of the breast: mammographic findings. *Radiology* 1991; **181**: 751–5. doi: https://doi.org/10.1148/radiology.181.3.1947092
34. Kalisher L, Rickert RR, Sharo RJ. Solitary peripheral papilloma of the breast: a radiologic-pathologic correlation of a benign lesion that may mimic breast cancer on mammography. *AJR Am J Roentgenol* 1998; **171**: 605–9. doi: https://doi.org/10.2214/ajr.171.3.9725282
35. Kiran S, Jeong YJ, Nelson ME, Ring A, Johnson MB, Sheth PA, et al. Are we overtreating intraductal papillomas? *J Surg Res* 2018; **231**: 387–94. doi: https://doi.org/10.1016/j.jss.2018.06.008
36. Rosen PP, Holmes G, Lesser ML, Kinne DW, Beattie EJ. Juvenile papillomatosis and breast carcinoma. *Cancer* 1985; **55**: 1345–52. doi: https://doi.org/10.1002/1097-0142(19850315)55:6<1345::AID-CNCR2820550631>3.0.CO;2-B
37. Kafadar MT, Anadolulu Z, Anadolulu Ali İhsan, Tarini EZ. Juvenile papillomatosis of the breast in a pre-pubertal girl: an uncommon diagnosis. *Eur J Breast Health* 2018; **14**: 51–3. doi: https://doi.org/10.5152/ejbh.2017.3828
38. Bhosale SJ, Kshirsagar AY, Sulhyan SR, Jagtap SV, Nikam YP. Invasive papillary breast carcinoma. *Case Rep Oncol* 2010; **3**: 410–5. doi: https://doi.org/10.1159/000321270
39. Sarica O, Uluc F, Tasmali D. Magnetic resonance imaging features of papillary breast lesions. *Eur J Radiol* 2014; **83**: 524–30. doi: https://doi.org/10.1016/j.ejrad.2013.12.007
40. Bhattarai N, Kanemaki Y, Kurihara Y, Nakajima Y, Fukuda M, Maeda I. Intraductal papilloma: features on Mr ductography using a microscopic coil. *AJR Am J Roentgenol* 2006; **186**: 44–7. doi: https://doi.org/10.2214/AJR.04.1600
41. Mansel RE, Webster D, Sweetland H. et al. CHAPTER 11 - The duct ectasia/periductal mastitis complex. In: Mansel R. E, ed.*Hughes, mansel & webster's benign disorders and diseases of the breast (Third edition*. Edinburgh: W.B. Saunders; 2009. pp. 163–94.
42. Zhang Y, Zhou Y, Mao F, Guan J, Sun Q. Clinical characteristics, classification and surgical treatment of periductal mastitis. *J Thorac Dis* 2018; **10**: 2420–7. doi: https://doi.org/10.21037/jtd.2018.04.22
43. Renz DM, Baltzer PAT, Böttcher J, Thaher F, Gajda M, Camara O, et al. Magnetic resonance imaging of inflammatory breast carcinoma and acute mastitis. A comparative study. *Eur Radiol* 2008; **18**: 2370–80. doi: https://doi.org/10.1007/s00330-008-1029-3
44. de Bazelaire C, Groheux D, Chapellier M, Sabatier F, Scémama A, Pluvinage A, et al. Breast inflammation: indications for MRI and PET-CT. *Diagn Interv Imaging* 2012; **93**: 104–15. doi: https://doi.org/10.1016/j.diii.2011.12.004
45. Oztekin PS, Durhan G, Nercis Kosar P, Erel S, Hucumenoglu S. Imaging findings in patients with granulomatous mastitis. *Iran J Radiol* 2016; **13**: e33900. doi: https://doi.org/10.5812/iranjradiol.33900
46. Poyraz N, Emlik GD, Batur A, Gundes E, Keskin S. Magnetic resonance imaging features of idiopathic granulomatous mastitis: a retrospective analysis. *Iran J Radiol* 2016; **13**: e20873. doi: https://doi.org/10.5812/iranjradiol.20873
47. Leong PW, Chotai NC, Kulkarni S. Imaging features of inflammatory breast disorders: a pictorial essay. *Korean J Radiol* 2018; **19**: 5–14. doi: https://doi.org/10.3348/kjr.2018.19.1.5
48. Fu P, Kurihara Y, Kanemaki Y, Okamoto K, Nakajima Y, Fukuda M, et al. High-resolution MRI in detecting subareolar breast abscess. *AJR Am J Roentgenol* 2007; **188**: 1568–72. doi: https://doi.org/10.2214/AJR.06.0099
49. Kijima Y, Matsukita S, Yoshinaka H, Owaki T, Aikou T. Adenoma of the nipple: report of a case. *Breast Cancer* 2006; **13**: 95–9. doi: https://doi.org/10.2325/jbcs.13.95
50. Tatterton MR, Fiddes R. Nipple adenoma: a review of the literature. *Ann Breast Surg* 2019; **3**: 3. doi: https://doi.org/10.21037/abs.2019.10.03
51. Lakhani SR, Ellis IO, Schnitt SJ, Tan PH, van de Vijver MJ. *WHO classification of tumours 4ed*. **4**. France: IARC Publications; 2012.
52. Matsubayashi RN, Adachi A, Yasumori K, Muranaka T, Ikejiri K, Yahara T, et al. Adenoma of the nipple: correlation of magnetic resonance imaging findings with histologic features. *J Comput Assist Tomogr* 2006; **30**: 148–50. doi: https://doi.org/10.1097/01.rct.0000188653.89398.7d
53. Omofoye TS, Scoggins ME, Dogan BE. Imaging approach to nipple masses. *Contemporary Diagnostic Radiology* 2015; **38**: 1–7. doi: https://doi.org/10.1097/01.CDR.0000473763.48551.cc

54. Adusumilli S, Siegelman ES, Schnall MD. MR findings of nipple adenoma. *AJR Am of Roentgenol* 2002; **179**: 803–4. doi: https://doi.org/10.2214/ajr.179.3.1790803
55. Buadu AA, Buadu LD, Murakami J, Murayama S, Hashiguchi N, Masuda K. Enhancement of the Nipple-Areolar-Complex on contrast-enhanced MR imaging of the breast. *Breast Cancer* 1998; **5**: 285–9. doi: https://doi.org/10.1007/BF02966709
56. Sakorafas GH, Blanchard DK, Sarr MG, Farley DR. Paget's disease of the breast: a clinical perspective. *Langenbecks Arch Surg* 2001; **386**: 444–50. doi: https://doi.org/10.1007/s004230100250
57. Lim HS, Jeong SJ, Lee JS, Park MH, Kim JW, Shin SS, et al. Paget disease of the breast: mammographic, us, and MR imaging findings with pathologic correlation. *Radiographics* 2011; **31**: 1973–87. doi: https://doi.org/10.1148/rg.317115070
58. Ashikari R, Park K, Huvos AG, Urban JA. Paget's disease of the breast. *Cancer* 1970; **26**: 680–5. doi: https://doi.org/10.1002/1097-0142(197009)26:3<680::AID-CNCR2820260329>3.0.CO;2-P
59. Karakas C. Paget's disease of the breast. *J Carcinog* 2011; **10**: 31. doi: https://doi.org/10.4103/1477-3163.90676
60. Kothari AS, Beechey-Newman N, Hamed H, Fentiman IS, D'Arrigo C, Hanby AM, et al. Paget disease of the nipple. *Cancer* 2002; **95**: 1–7. doi: https://doi.org/10.1002/cncr.10638
61. Ikeda DM, Helvie MA, Frank TS, Chapel KL, Andersson IT, et al. Paget disease of the nipple: radiologic-pathologic correlation. *Radiology* 1993; **189**: 89–94. doi: https://doi.org/10.1148/radiology.189.1.8396786
62. Sripathi S, Ayachit A, Kadavigere R, Kumar S, Eleti A, Sraj A. Spectrum of imaging findings in Paget's disease of the Breast-A pictorial review. *Insights Imaging* 2015; **6**: 419–29. doi: https://doi.org/10.1007/s13244-015-0415-z
63. Mossa-Basha M, Fundaro GM, Shah BA, Ali S, Pantelic MV, et al. Ductal carcinoma in situ of the breast: MR imaging findings with histopathologic correlation. *Radiographics* 2010; **30**: 1673–87. doi: https://doi.org/10.1148/rg.306105510
64. Cabioglu N, Krishnamurthy S, Kuerer HM, Hunt KK, Singletary SE, Meric-Bernstam F, et al. Feasibility of breast-conserving surgery for patients with breast carcinoma associated with nipple discharge. *Cancer* 2004; **101**: 508–17. doi: https://doi.org/10.1002/cncr.20394
65. Louie LD, Crowe JP, Dawson AE, Lee KB, Baynes DL, Dowdy T, et al. Identification of breast cancer in patients with pathologic nipple discharge: does ductoscopy predict malignancy? *Am J Surg* 2006; **192**: 530–3. doi: https://doi.org/10.1016/j.amjsurg.2006.06.004
66. Barreau B, Mascarel Ide, Feuga C, MacGrogan G, Dilhuydy M-H, Picot V, et al. Mammography of ductal carcinoma in situ of the breast: review of 909 cases with radiographic–pathologic correlations. *Eur J Radiol* 2005; **54**: 55–61. doi: https://doi.org/10.1016/j.ejrad.2004.11.019
67. Kuhl CK, Schrading S, Bieling HB, Wardelmann E, Leutner CC, Koenig R, et al. Mri for diagnosis of pure ductal carcinoma in situ: a prospective observational study. *Lancet* 2007; **370**: 485–92. doi: https://doi.org/10.1016/S0140-6736(07)61232-X
68. Greenwood HI, Heller SL, Kim S, Sigmund EE, Shaylor SD, Moy L. Ductal carcinoma in situ of the breasts: review of Mr imaging features. *Radiographics* 2013; **33**: 1569–88. doi: https://doi.org/10.1148/rg.336125055
69. Tozaki M, Igarashi T, Fukuda K. Breast MRI using the VibE sequence: clustered ring enhancement in the differential diagnosis of lesions showing non-masslike enhancement. *AJR Am J Roentgenol* 2006; **187**: 313–21. doi: https://doi.org/10.2214/AJR.05.0881
70. Jansen SA, Newstead GM, Abe H, Shimauchi A, Schmidt RA, Karczmar GS. Pure ductal carcinoma in situ: kinetic and morphologic MR characteristics compared with mammographic appearance and nuclear grade. *Radiology* 2007; **245**: 684–91. doi: https://doi.org/10.1148/radiol.2453062061
71. Rosen EL, Smith-Foley SA, DeMartini WB, Eby PR, Peacock S, Lehman CD. Bi-Rads MRI enhancement characteristics of ductal carcinoma in situ. *Breast J* 2007; **13**: 545–50. doi: https://doi.org/10.1111/j.1524-4741.2007.00513.x
72. Vag T, Baltzer PAT, Dietzel M, Benndorf M, Gajda M, Camara O, et al. Kinetic characteristics of ductal carcinoma in situ (DCIS) in dynamic breast MRI using computer-assisted analysis. *Acta Radiol* 2010; **51**: 955–61. doi: https://doi.org/10.3109/02841851.2010.508171
73. Obdeijn I-MA, Loo CE, Rijnsburger AJ, Wasser MNJM, Bergers E, Kok T, et al. Assessment of false-negative cases of breast MR imaging in women with a familial or genetic predisposition. *Breast Cancer Res Treat* 2010; **119**: 399–407. doi: https://doi.org/10.1007/s10549-009-0607-7
74. Chadashvili T, Ghosh E, Fein-Zachary V, Mehta TS, Venkataraman S, Dialani V, et al. Nonmass enhancement on breast MRI: review of patterns with radiologic-pathologic correlation and discussion of management. *AJR Am J Roentgenol* 2015; **204**: 219–27. doi: https://doi.org/10.2214/AJR.14.12656
75. Jiang L, Zhou Y, Wang Z, Lu X, Chen M, Zhou C. Is there different correlation with prognostic factors between "non-mass" and "mass" type invasive ductal breast cancers? *Eur J Radiol* 2013; **82**: 1404–9. doi: https://doi.org/10.1016/j.ejrad.2013.03.006
76. Mann RM, Hoogeveen YL, Blickman JG, Boetes C. MRI compared to conventional diagnostic work-up in the detection and evaluation of invasive lobular carcinoma of the breast: a review of existing literature. *Breast Cancer Res Treat* 2008; **107**: 1–14. doi: https://doi.org/10.1007/s10549-007-9528-5
77. Lopez JK, Bassett LW. Invasive lobular carcinoma of the breast: spectrum of mammographic, us, and MR imaging findings. *Radiographics* 2009; **29**: 165–76. doi: https://doi.org/10.1148/rg.291085100
78. Pal SK, Lau SK, Kruper L, Nwoye U, Garberoglio C, Gupta RK, et al. Papillary carcinoma of the breast: an overview. *Breast Cancer Res Treat* 2010; **122**: 637–45. doi: https://doi.org/10.1007/s10549-010-0961-5
79. Eiada R, Chong J, Kulkarni S, Goldberg F, Muradali D. Papillary lesions of the breast: MRI, ultrasound, and mammographic appearances. *AJR Am J Roentgenol* 2012; **198**: 264–71. doi: https://doi.org/10.2214/AJR.11.7922
80. Robertson FM, Bondy M, Yang W, Yamauchi H, Wiggins S, Kamrudin S, et al. Inflammatory breast cancer: the disease, the biology, the treatment. *CA Cancer J Clin* 2010; **60**: 351–75. doi: https://doi.org/10.3322/caac.20082
81. Cserni G, Charafe-Jauffret E, van Diest PJ. Inflammatory breast cancer: the pathologists' perspective. *Eur J Surg Oncol* 2018; **44**: 1128–34. doi: https://doi.org/10.1016/j.ejso.2018.04.001
82. van Uden DJP, van Laarhoven HWM, Westenberg AH, de Wilt JHW, Blanken-Peeters CFJM. Inflammatory breast cancer: an overview. *Crit Rev Oncol Hematol* 2015; **93**: 116–26. doi: https://doi.org/10.1016/j.critrevonc.2014.09.003
83. Raghav K, French JT, Ueno NT, Lei X, Krishnamurthy S, Reuben JM, et al. Inflammatory breast cancer: a distinct clinicopathological entity transcending histological distinction. *PLoS One* 2016; **11**: e0145534. doi: https://doi.org/10.1371/journal.pone.0145534
84. Le-Petross HT, Cristofanilli M, Carkaci S, Krishnamurthy S, Jackson EF, Harrell RK, et al. Mri features of inflammatory breast cancer. *AJR Am J Roentgenol* 2011; **197**: W769–76. doi: https://doi.org/10.2214/AJR.10.6157
85. Abe H, Schmidt RA, Shah RN, Shimauchi A, Kulkarni K, Sennett CA, et al. MR-directed

("Second-Look") ultrasound examination for breast lesions detected initially on MRI: MR and sonographic findings. *AJR Am J Roentgenol* 2010; **194**: 370–7. doi: https://doi.org/10.2214/AJR.09.2707

86. Panzironi G, Pediconi F, Sardanelli F. Nipple discharge: the state of the art. *BJR Open* 2019; **1**: 20180016. doi: https://doi.org/10.1259/bjro.20180016
87. Okazaki A, Hirata K, Okazaki M, Svane G, Azavedo E. Nipple discharge disorders: current diagnostic management and the role of fiber-ductoscopy. *Eur Radiol* 1999; **9**): : 583–90p.. doi: https://doi.org/10.1007/s003300050715
88. Cabioglu N, Hunt KK, Singletary SE, Stephens TW, Marcy S, Meric F, et al. Surgical decision making and factors determining a diagnosis of breast carcinoma in women presenting with nipple discharge. *J Am Coll Surg* 2003; **196**: 354–64. doi: https://doi.org/10.1016/S1072-7515(02)01606-X
89. Menon RS, van Geel AN. Cancer of the breast with nipple involvement. *Br J Cancer* 1989; **59**: 81–4. doi: https://doi.org/10.1038/bjc.1989.15
90. Wang J, Xiao X, Wang J, Iqbal N, Baxter L, Skinner KA, et al. Predictors of nipple-areolar complex involvement by breast carcinoma: histopathologic analysis of 787 consecutive therapeutic mastectomy specimens. *Ann Surg Oncol* 2012; **19**: 1174–80. doi: https://doi.org/10.1245/s10434-011-2107-3
91. Paepke S, Schmid R, Fleckner S, Paepke D, Niemeyer M, Schmalfeldt B, et al. Subcutaneous mastectomy with conservation of the Nipple-Areola skin. *Ann Surg* 2009; **250**: 288–92. doi: https://doi.org/10.1097/SLA.0b013e3181b0c7d8
92. Moon JY, Chang Y-W, Lee EH, Seo DY. Malignant invasion of the nipple-areolar complex of the breast: usefulness of breast MRI. *AJR Am J Roentgenol* 2013; **201**: 448–55. doi: https://doi.org/10.2214/AJR.12.9186
93. Sakamoto N, Tozaki M, Hoshi K, Fukuma E. Is MRI useful for the prediction of nipple involvement? *Breast Cancer* 2013; **20**: 316–22. doi: https://doi.org/10.1007/s12282-012-0338-1
94. Liao C-Y, Wu Y-T, Wu W-P, Chen C-J, Wu H-K, Lin Y-J, et al. Role of breast magnetic resonance imaging in predicting malignant invasion of the nipple-areolar complex: potential predictors and reliability between inter-observers. *Medicine* 2017; **96**: e7170. doi: https://doi.org/10.1097/MD.0000000000007170
95. Dent BL, Miller JA, Eden DJ, Swistel A, Talmor M. Tumor-to-Nipple distance as a predictor of nipple involvement: expanding the inclusion criteria for Nipple-Sparing mastectomy. *Plast Reconstr Surg* 2017; **140**: 1e–8. doi: https://doi.org/10.1097/PRS.0000000000003414